

Research Article

Malays. j. med. biol. res.



Risk of Neurodegeneration in Patients with Morgellons Disease: A Focus on the Potential Risk of Developing Alzheimer's

Jase Grimm*

University of the People, 595 E Colorado Blvd Suite 623, Pasadena, CA 91101, USA

*Email for Correspondence: grimm.jase@uncommonfruit.co

ABSTRACT

Morgellons disease is a distressing dermatologic condition which typically presents with multiple, non-healing skin lesions with filamentous protrusions. Initial presentation of the condition can often include various neurological symptoms with dermatologic symptoms. Common neurological symptoms include neuropathy, cognitive impairment, and dementia. Recent studies reveal that spirochetes are a causative agent of Morgellons disease. Chronic spirochete infection is strongly associated with neurodegeneration seen in dementia and Alzheimer's disease. This paper will provide a brief overview of Morgellons and Alzheimer's disease and will explore the possible risk of developing Alzheimer's in Morgellons patients.

Keywords: Morgellons disease, Alzheimer's disease, Neurodegeneration, Protrusion

Manuscript Received: 14 July 2021

Revised: 26 August 2021

Accepted: 03 Sept 2021

This article is licensed under a Creative Commons Attribution-NonCommercial 4.0 International License.

Attribution-NonCommercial (CC BY-NC) license lets others remix, tweak, and build upon work non-commercially, and although the new works must also acknowledge and be non-commercial.

INTRODUCTION

Morgellons Disease ("MD") is a debilitating cutaneous condition characterized by multiple slow or non-healing skin lesions. In majority of cases, the cutaneous lesions seen in MD are ulcerated with superficial infection. In almost all MD cases, patients have reported extrusion of fibres or filaments from the skin lesions. MD is a multi-system disease. Typically, the clinical manifestations of MD extend beyond dermatologic presentation and include neurologic, psychiatric, and somatic symptoms. Previously, the etiology of MD was unknown. Both infectious and psychiatric etiologies have been proposed for MD. Due to an unclear etiology, treatment for the condition remains controversial. A mixed treatment approach with anti-microbials, anti-psychotics, and anti-depressants is currently recommended for the used for the management of MD (Aung-Din et al., 2018).

Alzheimer's disease ("AD") is a neurodegenerative disorder characterized by neurofibrillary tangles ("NFT's"-accumulation of hyper phosphorylated tau protein) and neuritic plaques in the brain. These pathologic lesions develop due to the accumulation of amyloid-beta peptide (plaques) and tau protein (NFTs) in the brain. The medial temporal lobe and the neocortical structures of the brain are the most commonly affected areas (Breijyeh and Karaman, 2020). Fig. 1 shows the schematic illustration of the risk factors for AD (Armstrong, 2019). However, Fig. 2 presents the illustration of the study plan.

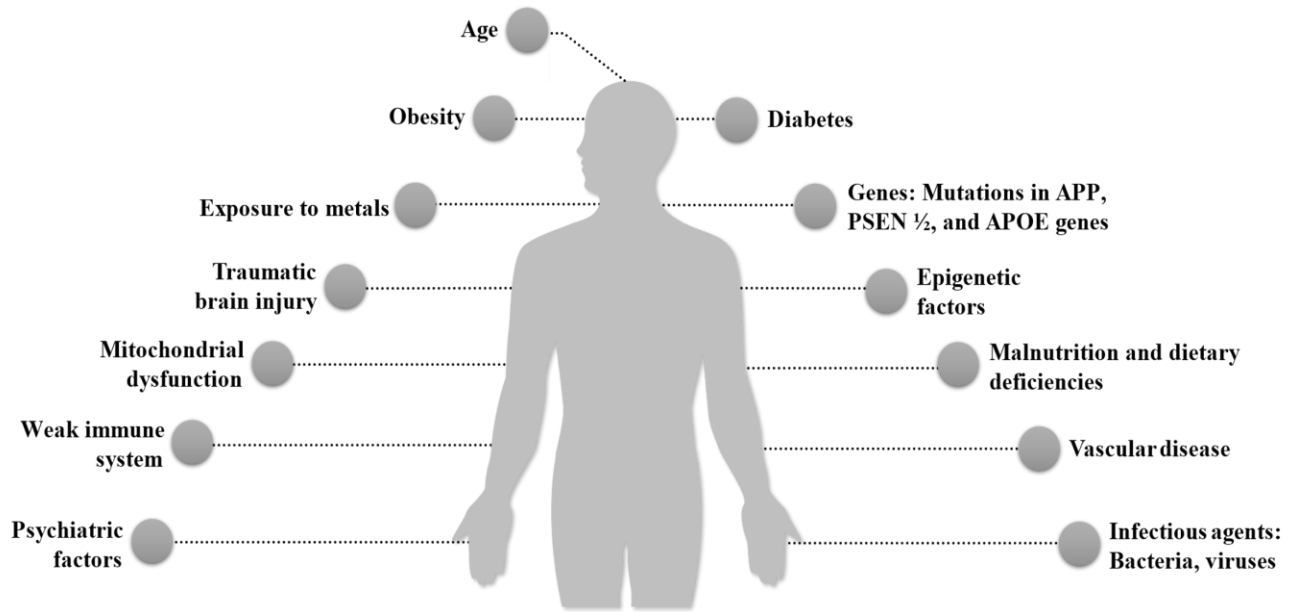


Figure 1: Schematic illustration of the AD risk factors

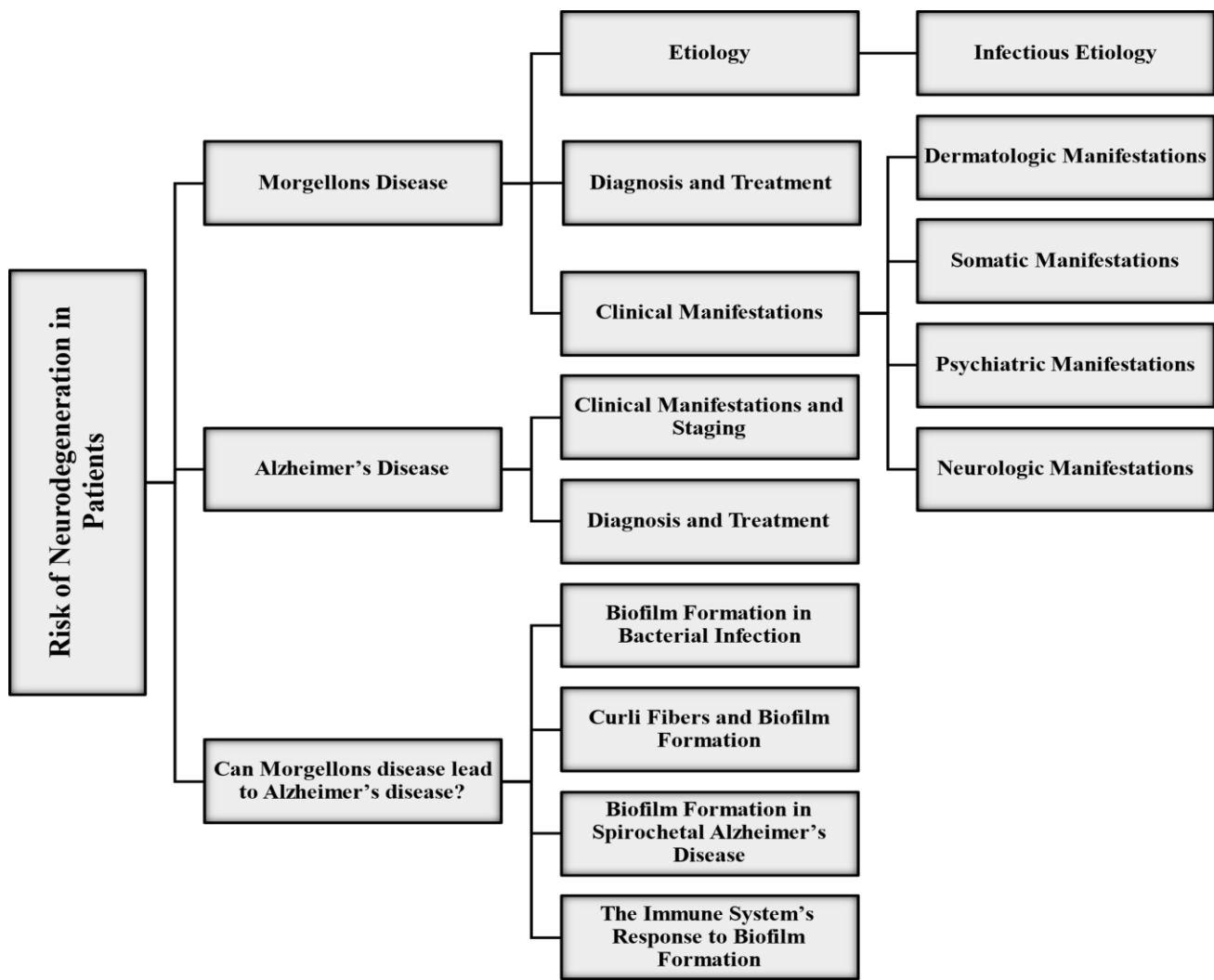


Figure 2: Study plan schematic illustration

MORGELLONS DISEASE

Etiology

Currently, the etiology of MD is believed to be multi-factorial. Although, in the past MD was considered by many researchers to be of psychiatric origin and was labelled as a Delusional Infestation (Middelveen et al., 2018). Most studies that reported MD to be a delusional disorder assessed the patient based on their clinical symptoms alone and didn't conduct histologic examination of the filaments found in the skin lesions or of the skin specimens and bodily fluids of MD patients. The theory of delusion was supported by many researchers as MD patients usually present with various somatic symptoms which were believed to have a psychiatric origin. As per some sources, as the filaments found in MD skin lesions resemble textile fibres, they were thought to be "delusions" of the patient. In recent years, MD has been established to be of infectious origin. However, as neuropsychiatric symptoms are observed in most MD patients, both psychiatric and infectious agents are thought to play a role in the development of the condition.

Infectious Etiology

The key infectious etiologic factor responsible for MD is reported to be *Borrelia spirochetes* (Bbss). Multiple studies have reported the detection of spirochetes in skin and bodily fluid specimens collected from MD patients. Besides spirochetes, three other species of *Borrelia* have also been detected in tissue and fluid samples of MD patients. These species are- *B. hermsii*, *B. garinii*, and *B. miyamotoi* (Middelveen et al., 2018).

Borrelia spirochetes can invade fibroblasts and keratinocytes and replicate within them. In vitro, spirochetes have been isolated from monolayers of fibroblasts and keratinocytes in spite of antibiotic therapy. Sequestration in these cells could be a contributing factor for development of refractory infection in MD patients.

In tissue samples of MD patients, microbes other than *Borrelia* spirochetes have been detected. These pathogens include *Helicobacter pylori*, *Bartonella henselae*, and *Treponema denticola* (Middelveen et al., 2018).

Clinical Manifestations

Dermatologic Manifestations: Gradual or non-healing cutaneous lesions with filaments. These filaments can be protruding from the lesion, or lie beneath the skin surface, or are embedded in the lesion. Filaments are either multi-colored (usually red, blue, yellow, and green) or they could be black or white. Histopathological reports reveal that these filaments are biofilaments produced by human epithelial cells (Middelveen and Stricker, 2016), as shown in Fig.3. Chiefly, these filaments are composed of keratin and collagen and are produced by activated keratinocytes and fibroblasts. Bacterial strains such as *Shewanella* and *H. pylori* have been found to produce filaments in in-vitro studies. Bacterial culture can confirm the spirochetal etiology of the condition and can be used to exclude other bacterial strains (Middelveen et al., 2018), (Middelveen and Stricker, 2016).

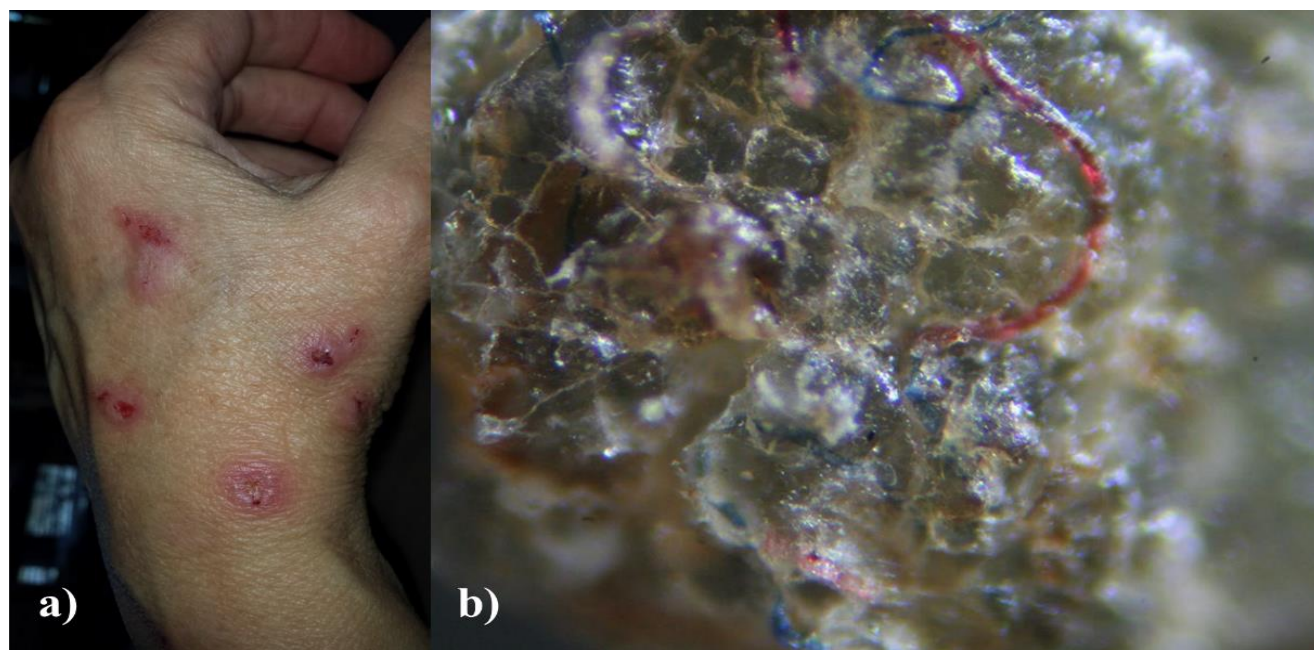


Figure 3: Morgellons disease patient (a) skin lesions on the hand, (b) Magnified image of multi-colored fibers in a skin lesion (Middelveen and Stricker, 2016)

Somatic Manifestations: Fatigue, joint pain, myalgia, burning or stinging sensation on skin, itching around the affected areas, and foreign body sensation on skin (a foreign/unfamiliar object is scratching the skin surface) (Aung-Din et al., 2018), (Middelveen and Stricker, 2016). With respect to its somatic manifestations, MD resembles Lyme disease (Middelveen and Stricker, 2016).

Psychiatric Manifestations: Studies indicate that patients with MD may present with one or more psychiatric conditions (Middelveen and Stricker, 2016). Commonly seen psychiatric disorders in MD patients include Obsessive Compulsive Disorder (OCD), Bipolar disorder, anxiety, depression, psychosis, and mania. Patients may also present with insomnia or schizophrenia.

Neurologic Manifestations: Neurologic symptoms associated with MD can range from marginal to critical. Cognitive impairment, irritability, neuropathy, insomnia, and dementia are seen in MD patients (Middelveen and Stricker, 2016).

At times, certain psychiatric manifestations of a patient may be similar to neurologic manifestations. Insomnia, neuropathy, twitching, trembling, and pins and needles sensation in the limbs can be seen in psychiatric disorders due to anxiety. Diagnostic tests such as CT and MRI scan can help to distinguish between psychiatric and neurological symptoms. Usually, symptoms of neurological origin have an underlying physical anomaly in the central or peripheral nervous system (Breijyeh and Karaman, 2020).

Diagnosis and Treatment

At present, there is no gold standard for the diagnosis of MD. The patient's clinical manifestations, histologic exam of filaments found in the skin lesions and pathologic exam of skin and bodily fluid specimens are used for the diagnosis of MD (Middelveen and Stricker, 2016). Management of MD comprises a combination of antibiotics, corticosteroids, and anti-psychotics. Anti-psychotics are particularly prescribed to patients who present with neuropsychiatric symptoms. Recently, low dose trifluoperazine has been found to be effective in managing psychiatric symptoms of MD patients (Aung-Din et al., 2018).

ALZHEIMER'S DISEASE

Clinical Manifestations and Staging

Alzheimer's disease is a leading cause of dementia. Common symptoms of Alzheimer's include progressive memory loss, impaired everyday activities, aphasia (speech impairment), agnosia (loss in perception), and apraxia (impaired motor neuron skills) (Breijyeh and Karaman, 2020).

The clinical phases of AD are broadly divided into pre-symptomatic and symptomatic phase. The pre-symptomatic phase can last for several years with mild memory loss. Pathologic changes in the cortex and hippocampus slowly occur in this phase, but there is no functional impairment and absence of symptoms. The symptomatic phase of Alzheimer's can be divided into the following stages (Breijyeh and Karaman, 2020):

- Mild or early stage: Mild memory loss, difficulty in concentrating, mood changes, disorientation of time and place. Some patients may develop depression.
- Moderate stage: Memory loss increases (patient can find it difficult to recognize family members and friends), difficulty in speaking, reading, and writing, loss of impulse control.
- Severe stage: Progressive functional and cognitive impairment, severe memory loss, difficulty in swallowing and urination. Over time, the complications of severe Alzheimer's can lead to the patient's death.

Diagnosis and Treatment

Diagnosis of Alzheimer's is made through observation of the patient's clinical symptoms, degree of dementia, use of biomarkers, and contrast-enhanced imaging that can detect traces of amyloid-beta peptide deposition in the affected brain areas (Weller and Budson, 2018). To date, no cure has been found for Alzheimer's. Currently, there are no known preventive measures for the condition. Therefore, available treatment aims to only alleviate the symptoms of the condition and slow the disease progression. Currently, only two classes of pharmacological drugs are prescribed for Alzheimer's patients. Cholinesterase inhibitors donepezil, galantamine, and rivastigmine are recommended for patients with Alzheimer's. These drugs can be prescribed for mild, moderate, and severe diseases. For patients with moderate to severe disease, Memantine- a dopamine agonist and N-methyl-D-aspartate receptor antagonist- is recommended.

CAN MORGELLONS DISEASE LEAD TO ALZHEIMER'S DISEASE?

The etiology of Alzheimer's disease is usually multi-factorial. Of the various risk factors, bacterial infectious agents are known to contribute to the development and progression of Alzheimer's. Research indicates that spirochetes are one of the most important bacterial etiologic agents of dementia, which is the chief presenting symptom in Alzheimer's patients (Sochocka et al., 2017).

Spirochetes are neurotropic pathogens that infect the brain, initiate the host defense mechanism and then pass into latent chronic infection. Within the body, these bacteria can spread through hematogenous dissemination, lymphatics, along the nerve fibres, and the fila olfactoria or tractus olfactorius. Chronic spirochete infection can cause serious brain disturbances such as disturbed capillary network, cerebrovascular lesions, and cerebral hypoperfusion.

An integral part of spirochetes are amyloidogenic proteins. Amyloids are significant for spirochetes as they contribute to bacterial virulence and also assist in invasion of host cells. Chronic spirochete infection leads to amyloid deposits. It is postulated that long-term spirochetal infection can contribute to amyloid-beta deposits seen in AD.

A growing body of literature suggests that various types of spirochetes can lead to brain damage and dementia. *Treponema pallidum* (*Spirochaetaceae*) can infect the cerebral cortex and cause cortical atrophy, amyloidosis, and slowly progressive dementia. Lyme disease (borreliosis) caused by another spirochete is associated with cortical atrophy microgliosis. The condition is often related to dementia. *B. burgdorferi*, a spirochete can cause neuro-degenerative changes in the brain through the induction of intracellular inflammation in neurons. The inflammation leads to abnormal tau phosphorylation, NFT generation, and microtubular dysfunction (microtubules are components within the cell that perform various cellular functions).

Treponema denticola is the most cultivable oral spirochete that is known to cause periodontal disease. Periodontal disease can cause recurrent oral infections. Spirochetal periodontal disease is related to AD as pathogens from the mouth can reach the Central Nervous System (CNS) via the bloodstream or peripheral nerves. Chronic oral spirochetal infection promotes inflammation and is a risk factor for AD (Sochocka et al., 2017).

Biofilm Formation in Bacterial Infection

Biofilms are bacterial communities characterized by complex three-dimensional structures, water channels, and increased resistance to environmental stress. Certain bacterial species, such as spirochetes, spin biofilms for their protection and survival within the host's body. The formation of a biofilm is a multi-step process that involves five main stages (Barnhart and Chapman, 2006). These stages are:

- Reversible attachment
- Irreversible attachment along with production of adhesive molecules (adhesions, exopolysaccharides)
- Biofilm development is characterized by the distinct mushroom shape
- Biofilm maturation
- Biofilm dispersal

In the biofilm developmental process, various bacterial surface structures, such as flagella, pili, exopolysaccharides, and curli fibers play different roles. However, the role of curli fibers in biofilm formation in spirochetal infection is of significance, as it is related to amyloid deposits seen in Alzheimer's.

Curli Fibers and Biofilm Formation

Enteric bacteria such as *Salmonella* spp. and *Escherichia coli* produce extracellular protein fibers known as curli. These fibers promote host colonization and bacterial community behaviour. Curli fibers are vital for biofilm formation. These fibers form the proteinaceous portion of the biofilm (Allen, 2016). They are immunogenic and are important for the attachment of biofilms. Biochemically and structurally, curli fibers are amyloids. Formation of amyloid fibers is associated with Alzheimer's (Barnhart and Chapman, 2006).

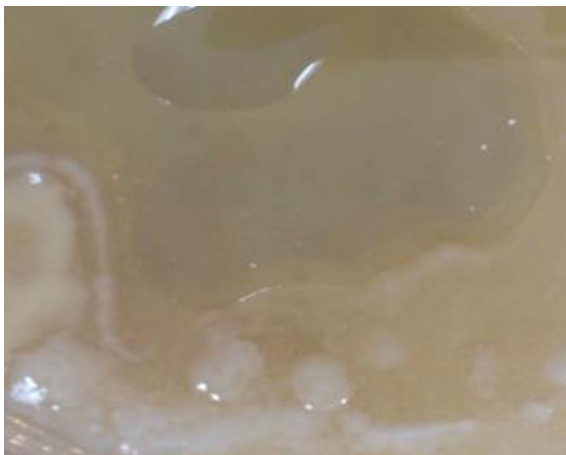

Figure 4: Biofilm representative "Slime" on gross examination (Allen, 2016)

Biofilm Formation in Spirochetal Alzheimer's Disease

Studies have revealed presence of spirochetes in the brain tissue of individuals affected with spirochete-induced Alzheimer's. The pathogenesis and progression of the disease is related to the stages of spirochetal colonization within the host tissue. Once spirochetes invade the brain tissue, they attach to the tissue surface and divide and multiply. The division and multiplication of the bacteria is an extremely slow process (Allen, 2016). After reaching a certain quorum, the bacteria begin to weave a biofilm. On gross examination, a biofilm appears to be encased in "slime", as shown in Fig. 4. Because of slow bacterial division, it could take about two years for the accumulation of sufficient bacterial population that can spin one biofilm. The very slow formation of bacterial colony is associated with the gradual development and progression of AD. Hence, the symptoms of AD can take years to appear.

The Immune System's Response to Biofilm Formation

The onset of biofilm formation relies on quorum sensing. Following the formation of a biofilm, the innate immune system is activated and tries to destroy the biofilm. The immune system releases Toll-like receptor 2 (TLR-2), which in turn generates Tumor Necrosis Factor-alpha (TNF-alpha) and Nuclear Factor- kb (NF-kB). Typically, when bacteria are free floating TLR-2 destroys microbes by first coating them and then releasing TNF- alpha and NF-kB which kill them. However, when microbes are protected by a biofilm, TLR-2 can't penetrate the biofilm. It has been theorized that because TNF- alpha and NF-kB produced by TLR-2 can't penetrate the biofilm, they instead destroy the neural tissue surrounding the biofilm (Allen, 2016). The neural tissue damage is irreversible, which is the main cause of dementia. This type of abnormal mechanism is observed in auto-immune conditions where the body's immune system goes awry and attacks its' own tissues leading to different conditions.

TREATMENT FOR SPIROCHETAL ALZHEIMER'S DISEASE

Due to the irreversible nature of the neural tissue damage, early diagnosis and prompt treatment of the condition is important. Treatment alone with a bactericidal antibiotic is futile, as first an agent has to be used to dispense the biofilm. Such agents include thiophenes (olanzapine), Piperidines (donepezil), furans (citalopram), pyrroles (azoles), and rifampicin. Combination therapy with a biofilm dispenser and an antibiotic is the appropriate treatment approach, as it can dispense the biofilms and also destroy the spirochetes (Allen, 2016).

CONCLUSION

Borrelia spirochete infection is one of the main etiologic factors in the development of Morgellons disease. Various research studies indicate a strong correlation between chronic spirochete infection and neurodegeneration in the brain, as seen in Alzheimer's disease. Based on this data, MD patients may have a high-risk of developing AD in the future due to chronic spirochete infection. However, to date, no research study has established a direct association between MD and AD. Further research in this area is needed to understand the risk of developing Alzheimer's in MD patients.

REFERENCES

- Allen, H. B. (2016). Alzheimer's disease: assessing the role of spirochetes, biofilms, the immune system, and amyloid- β with regard to potential treatment and prevention. *J. Alzheimer's Dis.*, 53(4.), 1271-1276.
- Armstrong, R. A. (2019). Risk factors for Alzheimer's disease. *Folia Neuropathol*, 57(2), 87-105.
- Aung-Din, D., Sahni, D. R., Jorizzo, J. L., and Feldman, S. R. (2018). Morgellons disease: insights into treatment. *Dermatol. Online J.*, 24(11).
- Barnhart, M. M. and Chapman, M. R. (2006). Curli biogenesis and function. *Annu. Rev. Microbiol.*, 60, 131-147.
- Breijyeh, Z. and Karaman, R. (2020). Comprehensive review on Alzheimer's disease: Causes and treatment. *Molecules*, 25(24), p. 5789.
- Middelveen, M. J. and Stricker, R. B. (2016). Morgellons disease: a filamentous borrelial dermatitis. *Int. J. Gen. Med.*, vol. 9, p. 349.
- Middelveen, M. J., Fesler, M. C., and Stricker, R. B. (2018). History of Morgellons disease: from delusion to definition. *Clin. Cosmet. Investig. Dermatol.*, 11, p. 71.
- Sochocka, M., Zwolinska, K. and Leszek, J. (2017). The infectious etiology of Alzheimer's disease. *Curr. Neuropharmacol.*, 15(7), 996-1009.
- Weller, J. and Budson, A. (2018). Current understanding of Alzheimer's disease diagnosis and treatment. *F1000Research*, vol. 7.